

Prolotherapy in chronic supraspinatus tendonitis

Marcelo de Pinho Teixeira Alves^{1*}, Stephen G Cavallino²

¹Médico Ortopedista, Mestre em Ciências Médicas; Hospital Dr. José Maria Grande, Portalegre, Portugal

²Médico Emergencista; European School of Prolotherapy, Ferrara, Italy

Correspondence

Marcelo de Pinho Teixeira Alves

Hospital Dr. José Maria Grande, Serviço de Ortopedia, 6º andar; Av. de Santo António, 7300-853 Portalegre, Portugal

- Received Date: 24 Apr 2021
- Accepted Date: 10 May 2021
- Publication Date: 15 May 2021

Keywords

prolotherapy; supraspinatus tendonitis; shoulder pain; shoulder tendonitis

Copyright

© 2021 Science Excel. This is an open-access article distributed under the terms of the Creative Commons Attribution 4.0 International license.

Abstract

Background: Supraspinatus tendonitis is a common cause of chronic shoulder pain and disability. Among the various types of treatment, prolotherapy has emerged as a non-surgical option.

Methods: Prolotherapy consists of the injection of a solution containing dextrose, saline solution and a local anesthetic. The authors present a series of 10 patients with chronic supraspinatus tendonitis, treated by only one session of prolo-therapy. The visual analogic pain scale (VAS) and the shoulder pain and disability index (SPADI) were used to evaluate the patients before and after the treatment.

Results: Pain as measured by the VAS was improved as well as disability as seen in SPADI scores.

Conclusion: The authors observed that only one session of the injection treatment can actually improve pain and disability inflicted by this condition. Prolotherapy can be used as a non-surgical option in the treatment of chronic supraspinatus tendonitis.

Introduction

WPain related to shoulder joint pathology is a common complaint among the general population, with many authors reporting a prevalence ranging from 6.9% to 34.0% [1]. After low back pain and neck pain, it is the third leading musculoskeletal complaint as reason for physician consultation [2]. It impacts the lives of manual workers, athletes and even the elderly, because shoulder pain and weakness interferes with work tolerance, sports, sleep and everyday self-care [3]. A large proportion of shoulder problems, especially with the increasing age, are related to rotator cuff disease [4-6].

There are numerous possibilities for treatments of this condition which depends upon the patients characteristics and complaints. Extremely important is the clinical physical examination and complimentary exams [1].

The American Academy of Orthopaedic Surgeons clinical practice guidelines for the management of rotator cuff problems suggest that patients with rotator cuff related symptoms, including tendinopathic changes to the supraspinatus tendon in the absence of full thickness tears, should initially be treated non-operatively [7].

These nonoperative modalities may include activity modification, nonsteroidal antiinflammatory drugs, physical therapy,

and various injection therapies, such as prolotherapy, platelet rich plasma, hyaluronic acid and corticosteroid injection. Operative management is generally reserved for selected patients or when nonoperative modalities have been exhausted [1].

Prolotherapy is a regenerative therapy which involves the injection of small volumes of an irritant agent, most commonly a hyperosmolar dextrose solution, at multiple painful tendon and ligament insertions where they connect to the bone. It can be necessary to perform several treatment sessions. The injection of dextrose initiates an inflammatory cascade at the site of injection, which causes fibroblast proliferation and subsequent collagen synthesis, resulting in a stronger tendon or ligament [7,8].

The purpose of this study is to show the results of a group of 10 patients with chronic shoulder pain caused by supraspinatus tendonitis treated with only one injection of dextrose prolotherapy.

Materials and methods

Patients

Each patient enrolled in this study signed an informed consent. The local institutional ethics committee approved this study.

Between February and September 2020, this prospective longitudinal controlled study

Citation: Alves M, Cavallino SG. Prolotherapy in chronic supraspinatus tendonitis. *Physiother Rehabil Res.* 2021; 1(1):1-5.

recruited 10 patients with chronic shoulder pain, who had symptoms for at least 6 months.

The patients were assigned to receive one injection treatment of prolotherapy treatment with 15% dextrose and were asked to return for control examination in 1, 8 and 16 weeks after the session.

The source population consisted of 10 patients referred to the orthopedic department for treatment of chronic shoulder pain further diagnosed with supraspinatus tendinopathy.

Patients criteria

Patients above 18 years old and with long-lasting symptoms of at least 6 months, refractory to at least 3 months of conservative methods, and chronic shoulder pain in the form of tendinosis or partial rotator cuff tear were included. Diagnosis was confirmed clinically by physical examination and ultrasonography.

The exclusion criteria were: full thickness supraspinatus tear, systemic inflammatory disease, osteomyelitis, active infection or history of chronic infection in the treatment area, previous operation on the shoulder, local corticosteroid injection within the previous 12 weeks, bleeding tendency (hereditary or acquired) and pregnancy.

Method

The injections were performed while the patient was sitting in an upright position. The specific injection point was the bony insertion of the distal attachment of the supraspinatus tendon.

Prolotherapy injections were applied under aseptic conditions using a 27G - 40mm needle. Each patient received only one injection prolotherapy treatment.

The 10 mL solution consisted in a mixture of 5mL 30% Dextrose diluted in 2 mL of 2% lidocaine and 3 mL of saline solution. The bony insertion of the distal attachment of the supraspinatus tendon received 4 needle punctures and

injections of a total of 2 mL of the solution.

After the injections, patients were instructed to rest the injected shoulder for 8 days, refrain from any heavy lifting activity and not to use anti-inflammatory drugs other than acetaminophen or paracetamol. If the pain became unbearable, patients were allowed to take 1000 mg of acetaminophen up to 3 times per day.

Assessment methods

Pain Visual Analogic Scale (VAS Score) was investigated using a visual analog scale, with 0 for absence of pain and 10 for severe pain. The VAS was assessed before the treatment and after 8 weeks and 16 weeks.

The Shoulder Pain and Disability Index (SPADI) was also used. This index was developed to measure current shoulder pain and disability in an outpatient setting. The SPADI contains 13 parameters that assess two domains: 5 parameters that measure pain and 8 parameters that measure disability (9). The measurement was made before the treatment and after 8 and 16 weeks. Absolute numbers were used.

Baseline characteristics were collected from all participants.

Follow-up examinations were performed on all of the patients at baseline, 8 and 16 weeks after the first treatment. Patients were requested to report any adverse effects at each visit.

Statistical analysis

The VAS score was used because the study focused on the effects of prolotherapy on diminishing the chronic shoulder pain.

The clinical data were presented as a number, percent, and mean ± SD.

Results

All 10 patients were available for evaluation at 8 weeks and 16 weeks post treatment. The Table 1 displays all patients at baseline, at eight weeks and at 16 weeks after the treatment.

Table 1. General data from the patients, before and after the treatment.

Patient Number	Age	M	F	VAS Before	VAS at 8 weeks	VAS at 16 weeks	SPADI Before	SPADI at 8 weeks	SPADI at 16 weeks
1	53		1	8	7	3	83	78	56
2	46		1	10	10	7	102	94	45
3	35		1	10	9	6	102	81	40
4	50		1	10	9	7	115	110	76
5	75		1	10	4	3	109	84	50
6	76		1	8	6	4	95	37	49
7	75		1	7	5	0	51	36	8
8	53	1		8	0	0	70	0	0
9	54		1	9	5	4	118	90	65
10	85		1	8	3	0	109	85	52
Medium:	60,2			8,8	5,8	3,4	95,4	69,5	44,1
Standard Deviation:	16,3			1,1	3,1	2,8	21,4	33,9	23,5

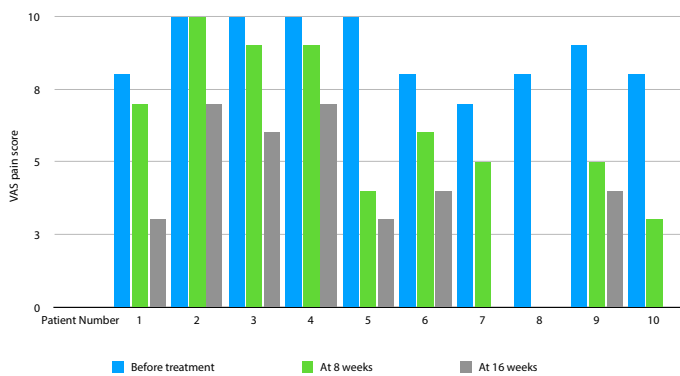


Figure 1. VAS values from all patients.

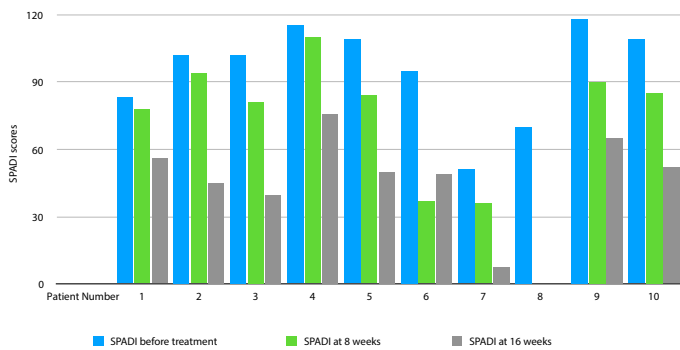


Figure 2. SPADI scores from all patients.

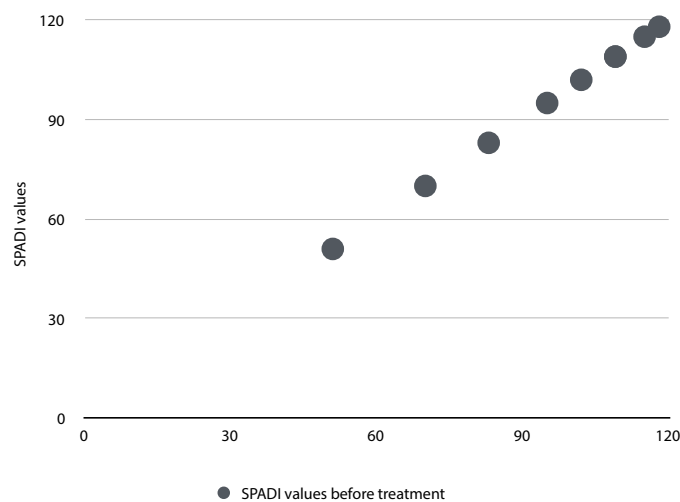


Figure 3. Distribution of patients' SPADI values before treatment.

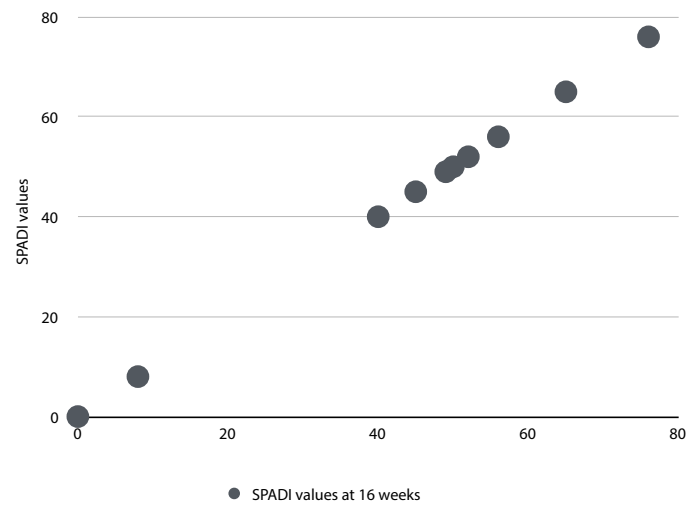


Figure 4. Distribution of patients' SPADI values at 16 weeks.

There were 9 females and 1 male patient. Medium age 60,2 years (standard deviation 16,3 years).

The authors observed improvement in the scores of pain, measured by the Visual Analogic Pain Scale (VAS): medium 8,8 before treatment, followed by a constant decrease: medium 5,8 at eight weeks and 3,4 at 16 weeks. Figure 1 displays VAS scores of all patients.

The medium SPADI Scores decreased from a medium 95,4 at baseline to 69,5 at eight weeks and 44,1 at 16 weeks of treatment. Figure 2 displays SPADI scores from all patients.

It was very noticeable that before the treatment, SPADI scores distribution showed the majority of patients between 90 and 120 points (Figure 3); after 16 weeks, we observed the distribution between 40 and 60 points (Figure 4).

None of the patients in the group experienced any serious complications (eg, bleeding, infection, cellulitis, septic joint).

Discussion

TRotator cuff tendinopathy is the leading cause of chronic shoulder pain in all age groups, especially with the increasing age. One can see in the current literature numerous non-surgical treatment modalities but still there is not a defined gold standard for its treatment [1,4,10].

The main objective in the treatment of rotator cuff disease is controlling the pain, as it is the most limiting factor for activity [8].

Many non-surgical procedures have been described for the treatment of rotator cuff tendinopathy, including platelet rich plasma rich injection, steroid injection, and sodium hyaluronate. But there are still many controversies and much needs to be more extensively studied [11-14].

Corticosteroid injections are the most used conventional method in the treatment of chronic shoulder pain [14], resulting in pain relief and functional improvement. But these injections have negative points, such as they do not improve

healing and may have harming side effects, for example focal inflammation, skin necrosis, tendon and ligament weakening or rupture and worsening osteoarthritic changes [14-16].

Despite its long history and broad use as a form of complementary treatment, the mode of action for hyperosmolar dextrose is unclear. Although there are controversies over its optimal indications, many studies have reported the use and efficacy of prolotherapy for various musculoskeletal conditions [8].

The proposed mode of action of dextrose prolotherapy is related to the observations that at concentrations greater than 10%, glucose is presumed to cause an osmotic gradient outside the cells where it is injected, causing some cells to lose water and lyse, leading to an influx of growth factors and inflammatory cells that are then assumed to initiate the wound-healing cascade in the local area, including the deposition of collagen [7,17].

Many authors, including two systematic reviews, described beneficial effects of prolotherapy injections in lateral epicondylitis, achilles tendinopathy, plantar fasciitis and trochanteric bursitis [18-20]. It may improve healing by stimulating the extracellular matrix, tightening and strengthening the ligaments and therefore enhancing the stability of the joints [3,8,21-27].

Given the similar pathologic findings of tendinopathies in different anatomic locations, it is believed that it is reasonable to try prolotherapy for other, less studied tendinopathies when first-line treatments fail [8,28].

Bertrand et al observed that dextrose prolotherapy significantly improved the number of participants who achieved a clinically-important improvement compared to superficial saline injection above painful entheses. In this work, which included 77 patients, they observed that at 9 months, 59% of the entheses-dextrose group maintained a 2.8 or more improvement in pain compared to 27% of the superficial-saline group [3]. Their results added to the body of randomized and controlled studies indicating a therapeutic benefit of dextrose prolotherapy in tendinopathy.

Lee et al. [8] used prolotherapy for patients with non-traumatic refractory rotator cuff disease who had 3 months of complaints. They performed 3 to 8 sessions of injections with an interval of 2 to 4 weeks, with an improvement in pain, disability, isometric strength, and shoulder motion.

A retrospective study of prolotherapy for chronic shoulder pain showed overall disability reduction from 81% of the patients prior to prolotherapy to 20% after the injection. 87% of patients had 50% or greater relief of their shoulder pain, improvement in sleep, and less reliance on analgesics, and patients were less anxious and depressed with the relief of pain, with 97% of these patients feeling that the Hackett-Hemwall technique of dextrose prolotherapy injection did change their life for the better [10].

When considering the complications of traditional treatments such as corticosteroid injections, prolotherapy is a safe and effective method [29], with a very low rate of complications. In a meta-analysis published in 2018, Lin et al showed that, for patients with rotator cuff tendinopathy, prolotherapy might yield better outcomes in the long term

(over 24 weeks) in pain reduction and functional improvement [30].

Prolotherapy is an invasive treatment method requiring in the majority of cases three injection sessions, which may seem to be excessive and costly. Some studies declared that the most effective benefits could be gained with repeated injections [1,31-33].

In this study, the authors performed only one injection session of prolotherapy, which provided good to excellent pain relief and improved function to patients with chronic shoulder pain, as seen by the VAS and SPADI scores. Our results were better than those observed by Lin et al [30], who noted only a two weeks relief of pain in their series. In their study, they performed only one session of prolotherapy injection, only in the supraspinatus insertion site. Our study showed that the improvement in pain and disability lasted for at least 16 weeks.

The most significant limitations of this study were its small sample size, lack of placebo control, and relative short follow-up. Therefore, larger studies with longer follow-up times may be necessary.

The authors agree with Bertrand et al [3] that this work has many strengths, especially for assessing a difficult and often refractory musculoskeletal condition with an innovative and safe treatment. The authors used a well-established functional questionnaire and an easy and user friendly visual analogic pain scale.

Conclusion

Prolotherapy is an easily applicable and satisfying non-surgical regenerative method in the treatment of chronic shoulder pain related to supraspinatus tendonitis. The results confirmed the hypothesis, as it has reduced pain and improved shoulder function with only one injection treatment.

Prolotherapy may provide an effective and welcome addition to the management of patients with painful shoulder tendinopathy.

References

1. Seven MM, Ersen O, Akpancar S, et al. Effectiveness of prolotherapy in the treatment of chronic rotator cuff lesions. *Orthop Traumatol Surg Res.* 2017;103(3):427-433.
2. Rekola KE, Keinänen-Kiukaanniemi S, Takala J. Use of primary health services in sparsely populated country districts by patients with musculoskeletal symptoms: consultations with a physician. *J Epidemiol Community Health.* 1993;47(2):153-157.
3. Bertrand H, Reeves KD, Bennett CJ, Bicknell S, Cheng AL. Dextrose prolotherapy versus control injections in painful rotator cuff tendinopathy. *Arch Phys Med Rehabil.* 2016;97(1):17-25.
4. Gruson KI, Ruchelsman DE, Zuckerman JD. Subacromial corticosteroid injections. *J Shoulder Elbow Surg.* 2008;17(1):118S-30S.
5. Varkey DT, Patterson BM, Creighton RA, et al. Initial medical management of rotator cuff tears: a demographic analysis of surgical and nonsurgical treatment in the United States Medicare population. *J Shoulder Elbow Surg.* 2016;25(12):e378-e385.
6. Schmidt CC, Jarrett CD, Brown BT. Management of rotator cuff tears. *J Hand Surg Am.* 2015;40(2):399-408.

7. Cole B, Lam P, Hackett L, Murrell GAC. Ultrasound-guided injections for supraspinatus tendinopathy: corticosteroid versus glucose prolotherapy - a randomized controlled clinical trial. *Shoulder Elbow*. 2018;10(3):170-178.
8. Lee DH, Kwack KS, Rah UW, Yoon SH. Prolotherapy for refractory rotator cuff disease: retrospective case-control study of 1 year follow up. *Arch Phys Med Rehab*. 2015;96(11):2027-2032.
9. Coombes BK, Bisset L, Vicenzino B. Efficacy and safety of corticosteroid injections and other injections for management of tendinopathy: a systematic review of randomised controlled trials. *Lancet*. 2010;376:1751-67.
10. George J, Li SC, Jaafar Z, Hamid MSA. Comparative effectiveness of ultrasound-guided intratendinous prolotherapy injection with conventional treatment to treat focal supraspinatus tendinosis. *Hindawi Sci*. 2018;1-7.
11. Kesikburun S, Tan AK, Yılmaz B, Yaşar E, Yazıcıoğlu K. Platelet-rich plasma injections in the treatment of chronic rotator cuff tendinopathy: a randomized controlled trial with 1 - year follow-up. *Am J Sports Med*. 2013;41(11):2609-2616.
12. Bergeson AG, Tashjian RZ, Greis PE, Crim J, Stoddard GJ, Burks RT. Effects of platelet-rich fibrin matrix on repair integrity of at-risk rotator cuff tears. *Am J Sports Med*. 2012;40(2):286-293.
13. Merolla G, Bianchi P, Porcellini G. Ultrasound-guided subacromial injections of sodium hyaluronate for the management of rotator cuff tendinopathy: a prospective comparative study with rehabilitation therapy. *Musculoskelet Surg*. 2013;97 Suppl 1:49-56.
14. Tillander B, Franzén LE, Karlsson MH, Norlin R. Effect of steroid injections on the rotator cuff: An experimental study in rats. *J Shoulder Elbow Surg*. 1999;8: 271-274.
15. Tempfer H, Gehwolf R, Lehner C, et al. Effects of crystalline glucocorticoid triamcinolone acetonide on cultured human supraspinatus tendon cells. *Acta Orthop*. 2009;80:357-62.
16. Stannard JP, Bucknell AL. Rupture of the triceps tendon associated with steroid injections. *Am J Sports Med*. 1993;21:482-485.
17. Lin KM, Wang D, Dines J. Injection therapies for rotator cuff disease. *Orthop Clin N Am* 2018;49:231-239.
18. Scarpone M, Rabago DP, Zgierska A, Arbogast G, Snell E. The efficacy of prolotherapy for lateral epicondylitis: a pilot study. *Clin J Sport Med*. 2008;18: 248-54.
19. Yelland MJ, Sweeting KR, Lyftogt JA, Ng SK, Scuffham PA, Evans KA. Prolotherapy injections and eccentric loading exercises for painful Achilles tendinosis: A randomised trial. *Br J Sports Med*. 2011;45:421-8.
20. Ryan MB, Wong A, Gillies J, Wong J, Taunton J. Sonographically guided intratendinous injections of hyperosmolar dextrose/lidocaine: A pilot study for the treatment of chronic plantar fasciitis. *Br J Sports Med*. 2009;43:303-6.
21. Di Paolo S, Gesualdo L, Ranieri E, Grandaliano G, Schena FP. High glucose concentration induces the overexpression of transforming growth factor-beta through the activation of a platelet-derived growth factor loop in human mesangial cells. *Am J Pathol*. 1996;149(6):2095-106.
22. Murphy M, Godson C, Cannon S, et al. Suppression subtractive hybridization identifies high glucose levels as a stimulus for expression of connective tissue growth factor and other genes in human mesangial cells. *J Biol Chem*. 1999;274(9):5830-4.
23. Krump E, Nikitas K, Grinstein S. Induction of tyrosine phosphorylation and Na⁺/H⁺ exchanger activation during shrinkage of human neutrophils. *J Biol Chem*. 1997;272(28):17303-11.
24. Rabago D, Patterson J, Mundt M, Kijowski R, Grettie J, Segal N. Dextrose prolotherapy for knee osteoarthritis: a randomised controlled trial. *Ann Fam Med*. 2013;11:229-237.
25. Kirkley A, Alvarez C, Griffin S. The development and evaluation of a disease-specific quality-of-life questionnaire for disorders of the rotator cuff: the Western Ontario Rotator Cuff Index. *Clin J Sport Med*. 2003;13:84-92.
26. Roach KE, Budiman-Mak E, Songsiridej N, Lertratanakul Y. Development of a shoulder pain and disability index. *Arthritis Care Res* 1991;4:143-9.
27. Lin CL, Huang CC, Huang SH. Effects of hypertonic dextrose injection on chronic supraspinatus tendinopathy of the shoulder: randomized placebo-controlled trial. *Eur J Phys Rehabil Med*. 2019;55(4):480-487.
28. Distel LM, Best TM. Prolotherapy: a clinical review of its role in treating chronic musculoskeletal pain. *PM R*. 2011;3:S78-81.
29. Nichols AW. Complications associated with the use of corticosteroids in the treatment of athletic injuries. *Clin J Sport Med*. 2005;15(5):370-375.
30. Lin MT, Chiang CF, Wu CH, Huang YT, Tu YK, Wang TG. Comparative effectiveness of injection therapies in rotator cuff tendinopathy: a systematic review, pairwise and network meta-analysis of randomized controlled trials. *Arch Phys Med Rehabil*. 2019;100(2):336-349.
31. Ekinci S, Tatar O, Akpancar S, Turgut H, Seven MM. A New Treatment Option in Osteoarthritis: Prolotherapy Injections. *J Arthritis*. 2016;5:197-8
32. Scarpone M, Rabago DP, Zgierska A, Arbogast G, Snell E. The efficacy of prolotherapy for lateral epicondylitis: a pilot study. *Clin J Sport Med*. 2008;18:248-54.
33. Seenauth C, Inouye V, Langland JO. Dextrose prolotherapy for chronic shoulder pain: A case report. *Altern Ther Health Med*. 2018;24(1):56-60.