

Analysis of Related Complications After Foldable Capsular Vitreous Body Implantation

Cong Ren^{1,2†}, Zhongen Li^{1,2†}, Gaolei Wang², Jing Pang¹, Bin Guo^{1,2*}

¹Affiliated Eye Hospital of Shandong University of Traditional Chinese Medicine, Jinan, 250002, China.

²Shandong University of Traditional Chinese Medicine, Jinan, 250014, China.

[†]First authors: Cong Ren and Zhongen Li contributed equally to this work.

Correspondence

Bin Guo

Affiliated Eye Hospital, Shandong University of Traditional Chinese Medicine, 48 Yingxiongshan road, Jinan 250002, China.

Tel.: +86-531-58859690

E-mail: guobin00002@126.com

- Received Date: 27 Oct 2023
- Accepted Date: 10 Nov 2023
- Publication Date: 14 Nov 2023

Keywords

artificial vitreous balloon; complications; treatment

Copyright

© 2023 Authors. This is an open-access article distributed under the terms of the Creative Commons Attribution 4.0 International license.

Abstract

Objective: To summarize related complications and treatment after Foldable Capsular Vitreous Body (FCVB) implantation. **Methods:** This is a retrospective case study.

Methods: A retrospective analysis was conducted on 37 patients (37 eyes) implanted with FCVB at the Affiliated Eye Hospital of Shandong University of Traditional Chinese Medicine from September 2019 to May 2023. Reasons for the operation of folding artificial vitreous balloon implantation: 27 eyes (73.0%) implanted during the second stage of oil extraction after suture of eyeball rupture injury, 7 eyes (18.9%) implanted after primary vitrectomy, 3 eyes (8.1%) implanted during the second stage of oil extraction of old retinal detachment, and average follow-up (14+) months.

Results: The main complications after FCVB surgery are: 13 eyes (35.1%) of anterior chamber blood accumulation in 9 cases (24.3%), early intraocular pressure rise in 6 cases (16.2%), corneal endothelial decompensation in 2 cases (5.4%), artificial vitreous balloon displacement; 1 case of artificial vitreous balloon prolapse (2.7%).

Conclusion: Common complications after FCVB surgery included anterior chamber blood accumulation, early intraocular pressure increase, corneal endothelial density, artificial vitreous balloon displacement, and artificial vitreous balloon prolapse.

Introduction

For patients with severe eye trauma and silicone oil-dependent eyes, to avoid eye atrophy and eye removal, maintaining the appearance of the eye as much as possible and finding an excellent intraocular filling substance have become key factors in treatment. As a new type of intraocular filling material, the folding artificial vitreous balloon not only does not cause an exclusion reaction in the eye, but also allows silicone oil to be filled to avoid emulsification [1]. It can play a supporting role in the eye, support retinal reduction, prevent or delay the occurrence of eye atrophy, and reduce corneal endothelial loss. The risk of complications such as compensation, maintenance of intraocular pressure, and retention of partial visual function are safe and effective in the treatment of severe eye trauma and silicone oil-dependent eyes [2]. FCVBI implantation treatment of severe eyeball rupture with missing eye contents and phase II implantation for silicone oil-dependent eyes can maintain eye shape and intraocular pressure for a certain period of time and reduce the burden of multiple operations for patients. However, the occurrence and treatment of postoperative complications during clinical observation are also key factors that determine the prognosis of patients and need to be further discussed.

Objects and methods

Object selection

Retrospective analysis of the clinical data of 37 patients (37 eyes) implanted with FCVB at the Affiliated Eye Hospital of Shandong University of Traditional Chinese Medicine from September 2019 to May 2023, including male 31 and female 6; with an average age of 53.7 ± 7 years. Reasons for folding artificial vitreous balloon implantation surgery were as follows: 27 eyes were implanted during the second stage of oil extraction after suturing the eyeball rupture injury (73.0%), 7 eyes were implanted after primary vitrectomy for patients with eyeball rupture injury (18.9%), and 3 eyes were implanted during the second stage of oil extraction of old retinal detachment (8.1%).

Inclusion criteria

(1) After suture for severe eyeball rupture injury, it is difficult to evaluate eyeball atrophy and poor prognosis; (2) eyeball atrophy after various eye traumas; (3) those who rely on silicone oil after vitrectomy cannot be removed; (4) International Standard Vision Table Examination Best Corrective Vision is less than 0.1 person. The exclusion criteria: (1) silicone allergy; (2) scar constitution; (3) one-eyed patients; (4) combined endophthalmitis, severe uveitis, and intraorbidity. This study was

Citation: Ren C, Li Z, Wang G, Pang J, Guo B. Analysis of Related Complications After Foldable Capsular Vitreous Body Implantation. Japan J Res. 2023;4(8):1-4.

approved by the Ethics Committee of the Eye Hospital Affiliated to Shandong University of Traditional Chinese Medicine to inform patients and their families or guardians of the relevant matters related to surgery and implants in detail before surgery and signed an informed consent form.

Surgical method

All patients underwent FCVB implantation and the operation was completed by the same doctor. During the operation, the corresponding model was selected according to the patient's age, eye axis (measured by A-ultrasound or Master), UBM examination, ophthalmic B-ultrasound, and eye CT. Surgical steps: the patient's supine position, 2% Lidocaine and 1.5% ropivacaine equal mixture 3 ml after block anesthesia, 2ml paravulbar anesthesia eye, routine disinfection. (1) scleral puncture knife upper nose, upper temporal and temporal 3 incisions, 3.5 mm from the cornea margin, routine silicone oil removal surgery or glass body Resection surgery, try to remove the blood accumulation in the vitreous cavity, relieve the tension of the retina and choroid, try to completely electrocoagulate the bleeding point during the operation to avoid postoperative bleeding, and perform laser photocoagulation at the bottom of the eye as needed; (2) circumferential for the iris if the iris is complete; (3) cut the upper conjunctiva along the edge of the cornea and separate the subconjunctival tendons Membrane tissue, make an incision parallel to the corneal margin 4.5 mm behind the temporal corneal margin (try to avoid the wound where the eyeball ruptures), 5 mm in length; (3) Fold the FCVB and install it into the injector, which pushes FCVB into the vitreous cavity from the upper temporal sclera incision to adjust the FCVB position In position, silicone oil is injected into the balloon, and the scleral casing is pulled out while pushing in the silicone oil; the 5-0 line fixes the balloon drainage valve to the sclera surface of the equator; (6) 8-0 absorbable sutures to stitch the subconjunctiva tissue and the spherical conjunctiva to cover the drainage valve. Anti-inflammatory agents and corticosteroids were administered throughout the body and locally postoperatively.

Follow-up

From January to December, the patient was followed up to observe whether the patient had complications such as anterior chamber blood accumulation, corneal endothelial decompensation, artificial vitreous displacement, and how to deal with them effectively after complications occurred.

Results

Atrial hemorrhage

Anterior atrial hemorrhage is the most common postoperative complication of FCVB implantation. The cause is analyzed to be residual vascular and ciliary body bleeding, which can also be a choroid hemorrhage. Therefore, sufficient electrocoagulation should be performed to prevent postoperative bleeding. If anterior chamber blood accumulation occurs before the end of the operation, it should be fully flushed. Atrial, keep the intraocular pressure stable, supplement the anterior chamber viscosity, and continue to apply hemostatic drugs after surgery. If it cannot be absorbed 1 week postoperatively, it is feasible to wash the anterior chamber and supplement a sufficient amount of viscous anterior chamber during the operation. Some of the upper choroidal cavity blood can enter the anterior chamber through ciliary separation cracks; therefore, during surgery and oil injection, the rectus hook is used to repeatedly press

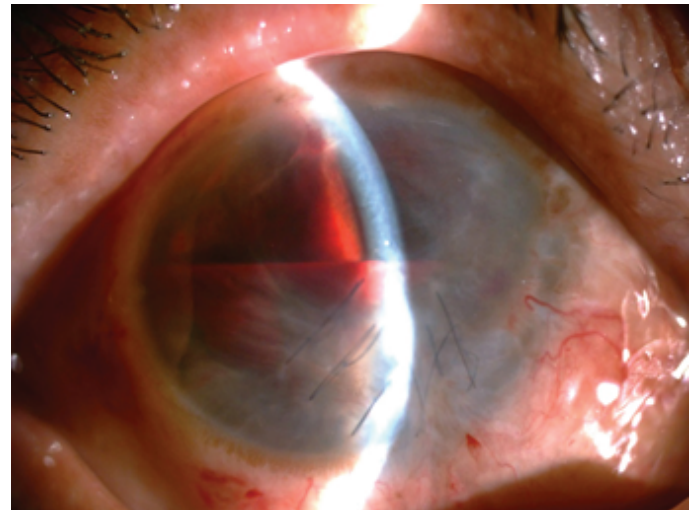


Figure 1. Anterior atrial hemorrhage.

the sclera to expel the upper choroid cavity [3]. This study found that 13 eyes (35.1%) developed anterior chamber blood accumulation after surgery, of which 10 eyes were absorbed after drug treatment, and the remaining three eyes were flushed 1 week after FCVB implantation. After the anterior chamber was flushed, it was injected with viscose, and no further bleeding occurred (Figure 1).

Early intraocular pressure increase

Patients with severe eye trauma often have low intraocular pressure and eye atrophy in the long term after surgery; however, this study showed 9 cases (24.3%) of early intraocular pressure increase after FCVB implantation, including 7 cases accompanied by anterior chamber blood accumulation. Analysis of the reasons is mostly caused by intraocular bleeding in the early postoperative period and blockage of the atrial angle with a large amount of viscous bullets in the anterior chamber. Most intraocular pressures return to normal or even low levels after symptomatic hemostasis, intraocular pressure-lowering drug treatment, and anterior chamber puncture and release. However, because it is highly related to intraocular bleeding and can easily aggravate early postoperative discomfort in patients, attention should still be paid to and accumulated. Extreme processing.

Corneal endothelial decompensation

6 cases (16.2%) of corneal endothelial decompensation after FCVB implantation; 6 patients did not have the preoperative corneal endothelial cell count detected, and 4 of them had anterior chamber blood accumulation after surgery. Because the patients included in the study had mostly serious eyeball rupture wounds before surgery, their corneal conditions were poor before surgery, and six patients had severe damage to the retinal choroid. Although the anterior chamber was filled with bullets during the operation, the possibility of anterior atrial blood accumulation remained high. Blood accumulation in the postoperative anterior chamber further aggravated the corneal endothelium injury, five out of six patients had serious iris injury, and FCVB had poor stability in the vitreous cavity, which could come into contact with the corneal endothelium and aggravate the development of corneal endothelial decompensation. Therefore, for patients with continuous corneal edema and anterior chamber blood accumulation after surgery, the anterior chamber blood accumulation should be flushed and injected with viscosity at an appropriate time when observing that the anterior

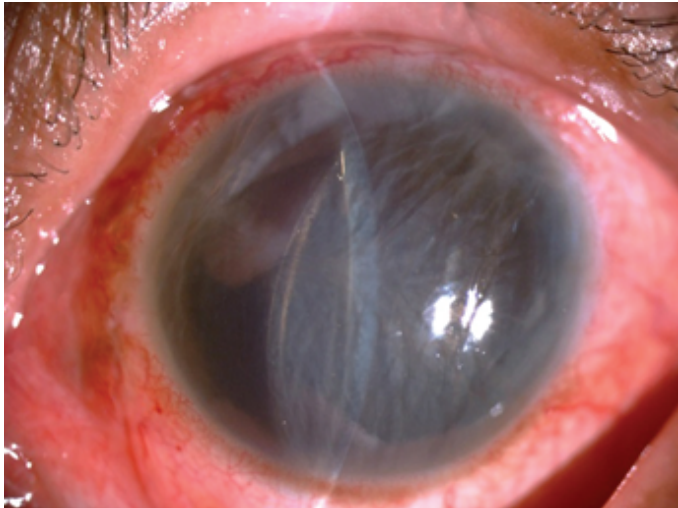


Figure 2. Artificial vitreous balloon dislocation.

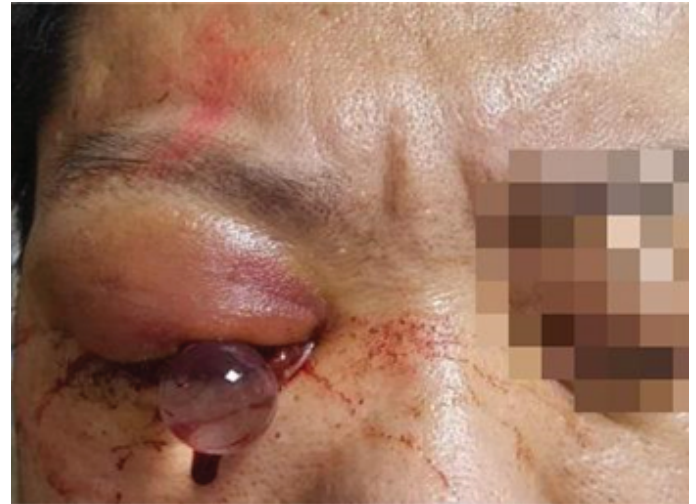

Figure 3. Artificial vitreous balloon prolapse.

chamber blood accumulation does not continue to absorb. For patients without iris eyes, FCVB can be intercepted and fixed by sutures during the operation to avoid contact and friction with the corneal endothelial surface and reduce the probability of corneal endothelial decompensation.

Artificial vitreous balloon dislocation

Two cases (5.4%) of FCVB-displaced patients had iris eyes without trauma, and no suture interception was performed during the surgery. One eye was an FCVB adjustment in January after displacement. The specific operation involved opening the original transparent corneal incision. After the viscous fluid forms the anterior chamber, the iris restorer adjusts the vitreous balloon to the positive position, and the FCVB is displaced again after the operation. After FCVB was followed up for half a year, it was found that the degree of displacement was small, the position was stable, and there was no contact with the corneal endothelial surface. For such patients, suture interception is feasible, and attention should be paid to screening patients without iris involvement during preoperative examination (Figure 2).

Artificial vitreous balloon prolapse

One case (2.7%), a patient with an eyeball rupture injury. During the first stage of eyeball rupture injury suture, the scleral laceration wound was located 5 mm after the 10 o'clock to 3 o'clock corneal margins. Eight days after the first suture operation, right front room washing, vitreous resection, and folding artificial vitreous balloon implantation were performed, during which most of the intraocular tissue was missing. After the necrotic tissue was removed, a 13.5P (eye axis 24) folding intraocular balloon was implanted, approximately 2.5 ml of silicone oil was injected, 250 ml of anti-inflammatory and hemostatic drugs were administered after surgery, and 250 ml of mannitol was administered as static drops. Seven hours after the surgery, the patient complained of an unbearable headache. He reported an intraocular pressure of T+2. After a small amount of hemorrhagic liquid was released along the transparent corneal puncture during the operation, the patient's symptoms were not relieved. No abnormalities were found on the emergency craniocerebral CT. CT showed that the artificial vitreous position was positive, the pain was relieved after the pain, and anti-reducine drugs were administered. The patient's pain was observed 15 h after the surgery. The glass balloon had prolapsed.

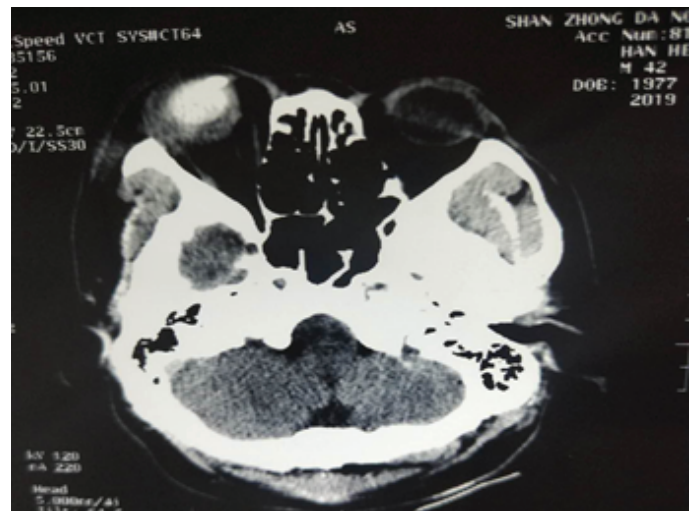


Figure 4. CT showed that the artificial vitreous position was positive. No abnormalities were found in the emergency craniocerebral CT.

Solution: Urgently perform the right eye vitreous balloon reduction operation, scraping out the eye content and returning the balloon during the operation, 6-0 non-absorbable suture to suture the original sclerasure wound. It is analyzed that 8 days after the suture of this patient's 8-0 absorbable suture, the wound has not healed well, the suture has begun to lose tension, and the bleeding has raised the intraocular pressure, which is the main cause of the balloon prolapse. The timing of FCVB implantation is critical. FCVB is riskier at the same time as vitrectomy for an eyeball rupture. to 2-3 months after vitrectomy, FCVB second-stage implantation surgery had a lighter reaction and fewer complications (Figure 3.4)

Conclusions

FCVB's material comes from specially modified liquid silicone rubber, which has good mechanical and optical properties [4]. It has high light transmission and laser irradiation stability and can withstand retinal laser photocoagulation treatment, which makes it possible to retain eyeballs in many patients with severe eye trauma. However, prevention and treatment of postoperative complications play a key role in prognosis. This

study summarizes and divides the complications in patients after FCVB implantation in our hospital. The analysis showed that for patients with severe eye trauma, the condition was stable after the first stage of vitrectomy, and the effect of the second phase of silicone oil extraction combined with FCVB implantation was better than that of FCVB implantation in the first stage; patients without iris may have FCVB bias or even corneal endothelial dysfunction after surgery, which should be screened when screening suitable patients more cautiously.

No abnormalities were found in the emergency craniocerebral CT.

Declarations

Ethics approval and consent to participate

Not applicable

Consent for publication

Not

Availability of data and materials

The data that support the findings of this study are available from the corresponding author upon reasonable request.

Conflicts of interest

The authors have declared no conflicts of interest.

Funding

This work was supported by the Shandong Provincial Medical Science and Technology Development Project (2018ws194) and the General Project of Natural Science Foundation of Shandong Province (ZR2020MH393).

Authors' contributions

CR and ZEL conceived and designed the study. GLW and JP performed the experiments. GLW and HS analyzed the data. CR and ZEL wrote the manuscript. BG confirm the authenticity of all the raw data. All authors read and approved the final manuscript.

Acknowledgments

The authors wish to acknowledge the help provided by the Laboratory of Eye Hospital Affiliated to Shandong University of Traditional Chinese Medicine.

References

1. Gao QY, Fu Y, Hui YN. Vitreous substitutes: challenges and directions. *Int J Ophthalmol.* 2015;8(3):437-440.
2. Xu X, Ge H, Li J, et al. Outcomes of a Foldable Capsular Vitreous Body Implantation: A Retrospective Study. *Dis Markers.* 2021;2021:6575195.
3. Jinchun J, Wang X, Xin L, et al. Clinical observation and experience of folding artificial vitreous balloon implantation in 73 cases. *International Journal of Ophthalmology* 2020; 20(11) : 1975-1978
4. Gao Q, Mou S, Ge J, et al. A new strategy to replace the natural vitreous by a novel capsular artificial vitreous body with pressurecontrol valve. *Eye (Lond).* 2008;22(3):461-468.
5. Liu Y, Jiang Z, Gao Q, et al. Technical standards of a foldable capsular vitreous body in terms of mechanical, optical, and biocompatible properties. *Artif Organs.* 2010;34(10):836-845.