



Hypophysitis In An Elderly Woman With COVID-19 - A Case Report

Alicia Rafaela Martinez Accioly¹, Isaura Romero Peixoto^{1,2*}, Felipe Alves Mourato Brasil³

¹Clinics Hospital of Pernambuco, Federal University of Pernambuco, Recife, Pernambuco, Brazil

²Post-Graduate Program in Tropical Medicine, Federal University of Pernambuco, Recife, Pernambuco, Brazil

³Post-Graduate in Biology Applied to Health, Federal University of Pernambuco, Recife, Pernambuco, Brazil.

Correspondence

Isaura Romero Peixoto

Clinics Hospital of Pernambuco, Federal University of Pernambuco, Recife, Pernambuco, Brazil

Abstract

We report a case of an 87-year-old woman with hyperactive delirium about seven days after diarrhea. Serology for COVID-19, collected at the time of behavioral symptoms, was positive. She evolved with a decreased level of consciousness and normal neuroimaging and electroencephalogram tests. Endocrinological investigation found dysfunction of the hypothalamic-pituitary axis, with a good response to hormone replacement. In conclusion, this report emphasizes the importance of being alert to atypical clinical manifestations and unusual complications against the background of Covid-19.

- Received Date: 08 Jun 2023
- Accepted Date: 14 Jun 2023
- Publication Date: 18 Jun 2023

Keywords: COVID-19; frail elderly; hypophysitis; Behavioral Symptoms; case report.

Copyright

© 2023 Authors. This is an open-access article distributed under the terms of the Creative Commons Attribution 4.0 International license.

Introduction

In December 2019, China notified the occurrence of new cases of pneumonia with unknown etiology to the World Health Organization (WHO) [1]. The new coronavirus had its genome sequenced - an RNA virus (SARS-Cov-2) and zoonosis belonging to the coronaviridae family [2] - and was established as the cause of these cases on January 2020 [3]. In February, WHO named this new disease as COVID-19, and recognized its pandemic status on March 11.

The clinical presentation of COVID-19 is diverse. Most cases (80.9%) are mild, 13.8% are classified as severe, and 4.7% as a critical case [4]. The conditions and risk factors associated with worse outcomes are advanced age, cardiovascular disease, diabetes, pneumopathies, hypertension, and neoplasms⁴. With the increasing world population age, there is a significant concern with the elderly, as they are people in the process of senescence with immunological vulnerability and multimorbidities [5].

The current literature on COVID-19 in the elderly reports that the most prevalent initial symptoms are hypo/hyperactive delirium, hypothermia, abdominal pain, and diarrhea [6]. Also, advanced age increases the risk and severity of complications after acute events [5]. Therefore, the objective of this paper is to describe a COVID-19 atypical presentation complicated with hypophysitis in a geriatric patient.

Case Report

An eighty-seven-year-old woman presented with a two-day report of diarrhea, without fever or respiratory symptoms. She had the following comorbidities: moderate Alzheimer's disease, ischemic heart disease with a history of myocardial revascularization and obesity, without continuous medication use. One week later, she developed delirium, psychomotor agitation, and hyperactive delirium. She was treated with levofloxacin for six days, which was stopped due to behavioral symptoms worsening.

Physical examination at this moment showed severe dehydration, aggressiveness, blood pressure of 110/60 mmHg, respiratory rate of 16 breaths per minute, heart rate of 81 beats per minute, and peripheral oxygen saturation of 92% in ambient air. Basal functionality, assessed by the Katz scale, scored 5/6; the same tool identified total dependence (score 0/6) on basic activities of daily living in the course of the current disease.

In-home care, treatment was initiated with venous hydration, management of constipation, and hyperactive delirium with intramuscular haloperidol followed by oral risperidone, with partial improvement.

Laboratory investigation showed positive serology for COVID-19 with chemiluminescence method (IgM 1.8 AU/ml and IgG 40.4 AU/L). Other laboratory tests showed: d-dimer 7113 ng/mL, serum C-reactive protein 1.23 mg/dL, ferritin 664 µg/L, hemoglobin 10.6 g/dL, platelets 94000/

Citation: Accioly ARM, Peixoto IR, Brasil FAM. Hypophysitis In An Elderly Woman With COVID-19 - A Case Report. Case Rep Rev. 2023;3(2):1-3.

mm³ and normal white series and thyroid hormones.

On day five, she required hospitalization due to consciousness level worsening without apparent cause. Admission exams showed serum C-reactive protein 18.37 mg/L, d-dimer 21520 ng/mL, lymphopenia 832/mm³, direct bilirubin 1 mg/dL, indirect bilirubin 1.5 mg/dL and INR 1.32. Cranium computer tomography without contrast showed no acute changes; chest tomography showed bilateral diffuse pulmonary infiltrate with ground-glass aspect and moderate pleural effusion on the right; abdominal tomography showed a gallbladder with thick walls and content, signs of chronic liver disease and mild ascites. She was treated empirically with piperacillin-tazobactam for six days, with clinical improvement. Lower limbs Doppler ultrasound identified bilateral distal deep venous thrombosis.

After this initial improvement, on the fifth day of hospitalization, the patient developed diarrhea, persistent drowsiness, hyporexia, hypersensitivity to cold, low tolerance to water supply, evolving to anasarca, and lower blood pressure levels.

Cranium Magnetic Resonance imaging without contrast (Figure 1) and electroencephalogram were performed, both without significant changes. After this constellation of nonspecific and persistent symptoms, the investigation of endocrine disorders was performed, showing low levels of morning serum cortisol (3.7 µg/L) and free T4 (0.7 ng/mL). Other laboratory tests showed dysfunction of the hypothalamic-pituitary axis at central level: TSH 0.71, ACTH <5 pg/mL, FSH 1.54 mUI/mL, LH 0.12 mUI/ml and prolactin 22.58 ng/ml.

Intravenous hydrocortisone was started every 8 hours at 100 mg/dose on the first day, followed by 50 mg/dose, with clinical improvement since the first day. After three days, hydrocortisone was replaced by 10mg oral prednisolone, and 12.5 mcg oral levothyroxine was started. It is important to emphasize that there is no report of previous use of corticosteroids. She was discharged on day 22 of hospitalization.

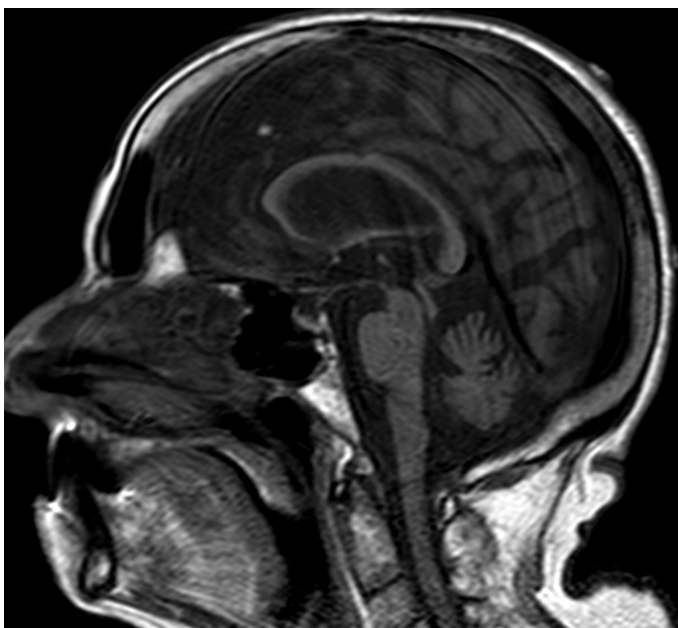


Figure 1. Magnetic resonance imaging showing a partially empty sella turcica, which can be considered normal for the patient's age.

Discussion

Aging is a complex process, and it is the product of genetic, environmental, stochastic, and epigenetic factors throughout life. Tissue senescence shares with chronic diseases a persistent, low-grade, and sterile inflammatory state, known as "inflammaging" [5]. The inflammaging represents a significant risk factor for elderly morbidity and mortality. Changes in the immune system in biological aging are related to low production of antibodies, evidenced in infectious diseases and even vaccines when unfavorable outcomes are observed [7].

The elderly patient has different manifestations, and vague and atypical symptoms characterize it. This type of presentation becomes more prevalent in older patients and has multimorbidities, polypharmacy, and cognitive impairment as significant risk factors [8]. The concept of health, when it comes to the elderly, goes beyond the absence of disease, involving functionality and quality of life. When these factors are altered, maybe represent a signal of underlying abnormality [9].

The new coronavirus has on its outer surface a large amount of an S protein (spike) that plays a key role in the entry of the virus into cells, as it recognizes the ACE2 receptor and interacts with it [10]. Studies have shown that rACE2 is expressed in pneumocytes and enterocytes. It is also found in the endothelium and smooth muscle cells [11,12]. Additionally, new evidence shows the expression of rACE2 in several regions of the central nervous system (CNS) [13]. Sequences of the SARS-cov genome were found in the cytoplasm of neurons of the hypothalamus and cerebral cortex [14]. However, no significant pathological changes were seen in the heart, pancreas, adrenal glands, and thyroid [14]. Possibly, the presence of other mechanisms, such as immune damage, vasculitis or hypoxia due to Severe Acute Respiratory Distress Syndrome (SARS), would justify the clinical and laboratory changes seen in clinical practice.

Hypopituitarism is the deficiency of one or more pituitary hormones caused by lesions in the hypothalamus-pituitary region [15]. The most common etiology is sellar and parasellar masses but also includes brain damage due to trauma or radiation, stroke, hypophysitis due to primary autoimmune diseases, infiltrative systemic diseases, chemotherapy, and infections [15]. The clinical manifestations correspond to the affected pituitary region: anterior lobe (adenohypophysitis), posterior lobe, and pituitary stem (infundibulohypophysitis) or both (panhypophysitis) [16].

It is believed that infectious hypophysitis can develop from hematogenous dissemination of systemic infections, CNS infections or even iatrogenic inoculation in trans sphenoid surgeries [15]. There are reports of hypophysitis after meningitis and meningoencephalitis caused by several microorganisms: tuberculosis, syphilis, parasites, fungi, and numerous viruses [15,17–19]. They may have partial or complete hormonal deficiencies, develop in the acute or late stages of infections, in addition to transient or permanent evolution [15].

Among viruses, cytomegalovirus, herpes simplex, varicella-zoster, influenza, coxsackie, hantavirus and enterovirus have already been associated with hypophysitis [20]. In 2005, a study with 61 SARS survivors found reversible hypothalamic-pituitary-adrenal / thyroid dysfunction within one year, suggesting that hypophysitis is a late pathological complication [21].

This worldwide threat, SARS-cov-2, which has the same pathogenic mechanism as the previous coronavirus and which is

known to affect several organs, including CNS [13], could cause dysfunctions of the hypothalamic-pituitary axis. The patient from this case report presented a clinical of hypothyroidism and hypocortisolism after developing COVID-19 with atypical presentation. The difficulty in diagnosing endocrine disorder was due to nonspecific and subacute symptoms, in addition to being an unexpected complication of a recent infectious disease. The investigation revealed central axis dysfunction, with clinical and laboratory manifestations suggestive of adenohypophysitis.

In addition to the possible direct damage in the hypothalamic-pituitary region, the immune mechanism could also be a cause since the so-called "cytokine storm" is described as an essential factor in the later phase of COVID-19 [22]. The signs and symptoms of hormonal deficiency in this case report manifested after the third week of symptom onset. Neuroimaging exams did not show ischemia or hemorrhage, which would be other forms of involvement, although damage to the microvasculature by vasculitis, emboli or thrombus, may not be evident by these methods. Abscesses were also not found.

The patient did not present severe hypoxemia or hemodynamic instability that would trigger transient ischemic events. As no other neurological findings were found in the clinical examination and she had improved sleepiness after hormone replacement, the cerebrospinal fluid examination was not necessary.

It is known that neuroendocrine disorders cause a wide range of nonspecific, multisystemic, psychiatric and cognitive signs and symptoms. These numerous clinical presentations often lead to delays or underdiagnoses, especially in the elderly with multiple morbidities. Consequently, there are significant impacts on quality of life and functionality, exacerbations, and faster progressions of previous diseases and even death [19].

The patient was known to have heart disease, dementia, and obesity. She evolved with decompensation of chronic liver disease, not previously known, in addition to significant functional impairment and cognitive-behavioral worsening during COVID-19 infection and after the development of endocrine deficiencies. We do not know how much of these losses can be recovered, especially in the context of an elderly patient with multiple comorbidities. However, we believe that multi-professional rehabilitation and longitudinal monitoring are essential for maximum recovery.

Conclusion

Elderly people are at risk for more significant morbidity and mortality due to COVID-19 infection. In addition to typically presenting symptoms distinct from the general population, they may have many morbidities that can mask this condition. In this case report, we present an elderly patient with an atypical course of infection by COVID-19 who developed hypophysitis. Also, we have shown that this disease offers great diagnostic complexity and is an additional risk to this population.

References

- World Health Organization. Novel Coronavirus (2019-nCoV) SITUATION REPORT - 1 21 JANUARY 2020. 2020.
- Zhu N, Zhang D, Wang W, et al. A Novel Coronavirus from Patients with Pneumonia in China, 2019. *N Engl J Med* 2020;382(8):727–33.
- Coronaviridae Study Group of the International Committee on Taxonomy of Viruses. The species Severe acute respiratory syndrome-related coronavirus: classifying 2019-nCoV and naming it SARS-CoV-2. *Nat Microbiol.* 2020;5:536–544.
- Epidemiology Working Group for NCIP Epidemic Response CC for DC and P. The epidemiological characteristics of an outbreak of 2019 novel coronavirus diseases (COVID-19) in China. *Zhonghua Liu Xing Bing Xue Za Zhi.* 2020;41(2):145–51.
- Franceschi C, Garagnani P, Parini P, Giuliani C, Santoro A. Inflammaging: a new immune–metabolic viewpoint for age-related diseases. *Nat Rev Endocrinol.* 2018;14(10):576–90.
- Tay HS, Harwood R. Atypical presentation of COVID-19 in a frail older person. *Age Ageing.* 2020;49(4):523–4.
- Rinaldi S, Pallikkuth S, George VK, et al. Paradoxical aging in HIV: immune senescence of B Cells is most prominent in young age. *Aging (Albany NY).* 2017;9(4):1307–25.
- Hofman MR, Van Den Hanenberg F, Siersevelt IN, Tulner CR. Elderly patients with an atypical presentation of illness in the emergency department. *Neth J Med.* 2017;75(6):241–6.
- César CC, De Mambrini JVM, Ferreira FR, Lima-Costa MF. Capacidade funcional de idosos: Análise das questões de mobilidade, atividades básicas e instrumentais da vida diária via Teoria de Resposta ao Item. *Cad Saude Publica.* 2015;31(5):931–45.
- Zhang X, Li S, Niu S. ACE2 and COVID-19 and the resulting ARDS. *Postgrad Med J.* 2020;96(1137):403–407.
- Hamming I, Timens W, Bulthuis M, Lely A, Navis G, van Goor H. Tissue distribution of ACE2 protein, the functional receptor for SARS coronavirus. A first step in understanding SARS pathogenesis. *J Pathol.* 2004;203(2):631–7.
- Natoli S, Oliveira V, Calabresi P, Maia LF, Pisani A. Does SARS-Cov-2 invade the brain? Translational lessons from animal models. *Eur J Neurol.* 2020;27(9):1764–73.
- Zubair AS, McAlpine LS, Gardin T, Farhadian S, Kuruvilla DE, Spudich S. Neuropathogenesis and Neurologic Manifestations of the Coronaviruses in the Age of Coronavirus Disease 2019: A Review. *JAMA Neurol.* 2020;77(8):1018–1027.
- Gu J, Gong E, Zhang B, et al. Multiple organ infection and the pathogenesis of SARS. *J Exp Med.* 2005;202(3):415–24.
- Pekic S, Popovic V. Diagnosis of endocrine disease: Expanding the cause of hypopituitarism. *Eur J Endocrinol.* 2017;176(6):R269–82.
- Kluczyński Ł, Gilis-Januszczyńska A, Rogoziński D, Pantofliński J, Hubalewska-Dydejczyk A. Hypophysitis — new insights into diagnosis and treatment. *Endokrynol Pol.* 2019;70(3):260–9.
- Dhanwal DK, Vyas A, Sharma A, Saxena A. Hypothalamic pituitary abnormalities in tubercular meningitis at the time of diagnosis. *Pituitary.* 2010;13(4):304–10.
- Tarvainen M, Mäkelä S, Mustonen J, Jaatinen P. Autoimmune polyendocrinopathy and hypophysitis after Puumala hantavirus infection. *Endocrinol Diabetes Metab Case Reports.* 2016;2016(10):4–9.
- Yuen KCJ, Popovic V, Trainer PJ. New causes of hypophysitis. *Best Pract Res Clin Endocrinol Metab.* 2019;33(2):101276.
- Prete A, Salvatori R. Hypophysitis [Internet]. *Endotext.* 2018 [cited 2018 Aug 15]; Available from: www.endotext.org.
- Leow MK-S, Kwek DS-K, Ng AW-K, Ong K-C, Kaw GJ-L, Lee LS-U. Hypocortisolism in survivors of severe acute respiratory syndrome (SARS). *Clin Endocrinol (Oxf).* 2005;63(2):197–202.
- Ye Q, Wang B, Mao J. The pathogenesis and treatment of the 'Cytokine Storm' in COVID-19. *J Infect* 2020;80(6):607–13.